

REVIEW ARTICLE

Intensive Training in Breast Imaging With Artificial Intelligence and Deep Learning- A Review Article

Debopriya Ghosh^{1*}, Ekta Ghosh², Debdutta³¹Department of Physiology, University College of Medical Sciences, New Delhi, India²Department of Pediatrics, All India Institute of Medical Science – New Delhi, India³Department of Computer Science, IIT BHU, India**Corresponding Author :** Debopriya Ghosh (d3bopr1ya@gmail.com)

Received 21 March 2022 | Revised 21 June 2022 | Accepted 28 June 2022 | Available Online July 05 2022

Citation: Debopriya Ghosh, Ekta Ghosh, Debdutta (2022). Intensive Training in Breast Imaging With Artificial Intelligence and Deep Learning- A Review Article. *Acta Biology Forum*. V01i01, 18-26. DOI: <https://doi.org/10.5281/zenodo.7008961>

ABSTRACT

To lower breast cancer morbidity and mortality, millions of breast imaging tests are carried out year. Breast imaging tests are carried out for cancer screening, diagnostic evaluation of suspicious findings, assessing the severity of the illness in patients who have just been diagnosed with breast cancer, and assessing treatment response. However, the interpretation of breast imaging can be arbitrary, laborious, slow, and open to human error. Deep learning (DL) has a great potential to perform medical imaging tasks at or above human-level performance, and may be used to automate parts of the breast cancer screening process, increase cancer detection rates, reduce needless call-backs and biopsies, improve patient risk assessment, and create new opportunities for disease prognostication. Retrospective and small reader studies support this claim. In order to verify these suggested tools and open the door to actual therapeutic application, prospective studies are urgently required. To meet the distinct ethical, medico legal, and quality control challenges that DL algorithms provide, new regulatory frameworks must also be created. In this paper, we cover the fundamentals of DL, present current DL breast imaging applications, such as cancer diagnosis and risk prediction, and talk about the difficulties and potential paths for AI-based breast cancer systems.

Keywords: Deep Learning (DL), Artificial Intelligence, Breast Imaging, Digital Breast Tomosynthesis and Mammography

INTRODUCTION

The area of medical imaging offers significant potential for change because to artificial intelligence (AI). Recent developments in computer algorithms, expanded computing availability power, and more people having access to large data, are this uprising. AI software may be trained to extract huge data sets with patterns, including sets with a large number of medical photos, and they can meet, even go beyond, human-level performance over a range of repeating well specified tasks. The development of AI algorithms is particularly well suited for breast imaging since the diagnosis problem is simple and data is widely available. The majority of breast imaging

tests are binary classification issues (e.g., malignant vs. benign), and practically all studies include a ground truth that is generally available for use during algorithmic development (e.g., histology or negative imaging follow-up). Additionally, population-wide screening programmes have made standard imaging data widely accessible, and the American College of Radiology (ACR) Breast Imaging and Reporting Data System (BI-RADS) system requires organised reporting and evaluations. To date, retrospective and small reader studies have demonstrated that AI technologies may be used to predict treatment response, enhance breast cancer risk assessment, improve diagnostic accuracy, and perform other jobs. AI is also being used to enhance image reconstruction

generally, allowing for the acquisition of high-quality pictures in MRI and mammography procedures with less radiation exposure and shorter scan periods. AI is in a unique position to assist breast imagers at both interpretative extremes. On the one hand, AI may be used to automate straightforward activities, such as eliminating entirely normal examinations from the radiology work list so radiologists can focus on more difficult patients. Computer algorithms are ideally suited for simple repetitive operations that people may find monotonous or tiresome since they do not get tired or distracted. However, AI has the potential to expand the boundaries of medical practise. AI is able to spot intricate patterns in imaging data that are invisible to the human eye, providing a wealth of knowledge that makes it possible to model diseases more accurately and personalise treatment plans. The generalizability of results is constrained by the fact that nearly all research conducted to far have been retrospective trials or small reader studies. Prospective studies are now required to more thoroughly assess these AI technologies' performance and are a requirement for responsible clinical translation. The principles of artificial intelligence (AI) and deep learning will be covered in this article, along with a variety of AI applications in clinical breast imaging. We'll also discuss challenges and possible directions for future study.

Deep Learning and Artificial Intelligence

Computer-aided detection (CAD) software for mammography was created in the 1990s and 2000s using traditional machine learning, a branch of artificial intelligence. Initial studies [18] showed that CAD increased diagnostic precision; it was approved by the FDA in 1998 and saw widespread adoption during the ensuing 18 years [19]. But more recent, bigger trials showed that CAD produces a lot of false positives and does not increase diagnostic accuracy, therefore it has mostly lost popularity. When AlexNet decisively defeated the competition in the Image Net Large Scale Visual Recognition Challenge in 2012, deep learning (DL), a new kind of representational machine learning, initially attracted notice [21]. An enormous amount of work has been put towards using DL in diagnostic radiology, and breast imaging in particular, since 2016. [22, 23] without consulting experts, DL models determine which imaging characteristics are necessary to conduct this classification in addition to classifying input pictures as positive or negative [24].

In contrast, classic machine learning methods (such as CAD) rely on manually created characteristics (such as shape and margin) to conduct categorization (Figure 1a). This significant distinction explains why modern DL algorithms outperform conventional machine learning approaches (if there is enough data available). Convolutional neural networks are typically used in DL algorithms for medical imaging (CNN). In order to extract hierarchical patterns from data, CNNs need millions of weights (i.e., variables to be optimised) and numerous levels of processing. The majority of deep learning (DL) models for medical imaging employ supervised learning, which calls for extensive usage of labelled training data.

Data labelling can be done at various levels, including the exam level (for example, the entire mammogram exam can be classified as benign or malignant), the breast level (for example, the left breast can be classified as benign while the right breast is classified as malignant), the pixel level (for example, the area of malignancy can be circled), and anywhere in between. Despite being expensive to produce, pixel-level labelling provides the most details and decreases the amount of training data that must be used. A general purpose learning procedure is utilised during CNN training to concurrently and autonomously execute feature selection and classification (Figure 1b). Numerous tagged medical pictures are delivered directly into a CNN during training. The top layer picks up on tiny, straightforward features (such the position and orientation of edges), the next levels pick up on specific combinations of those simpler features, and the deeper layers pick up on even more intricate configurations of those earlier patterns. The last layers categorise the image or look for other interesting patterns using these imaging attributes or representations (Figure 1b). A held-out test set that wasn't utilised during training is used to evaluate a CNN's performance after it has been completely trained. Ideally, a data set is used to further validate CNN's performance. Since DL approaches are data-driven, outcomes often get better as data set size rises. Although training data sets must be sufficiently wide and diverse to include the range of phenotypes of the categories that they intend to categorise, there is no established formula for determining the number of data sets required to train a model for a given job. When building a large enough data set to train a CNN from scratch is not doable CNN weights (a common occurrence in medical imaging). Initialised using weights acquired from a previous job (For instance, categorising cats and dogs). This method of transfer

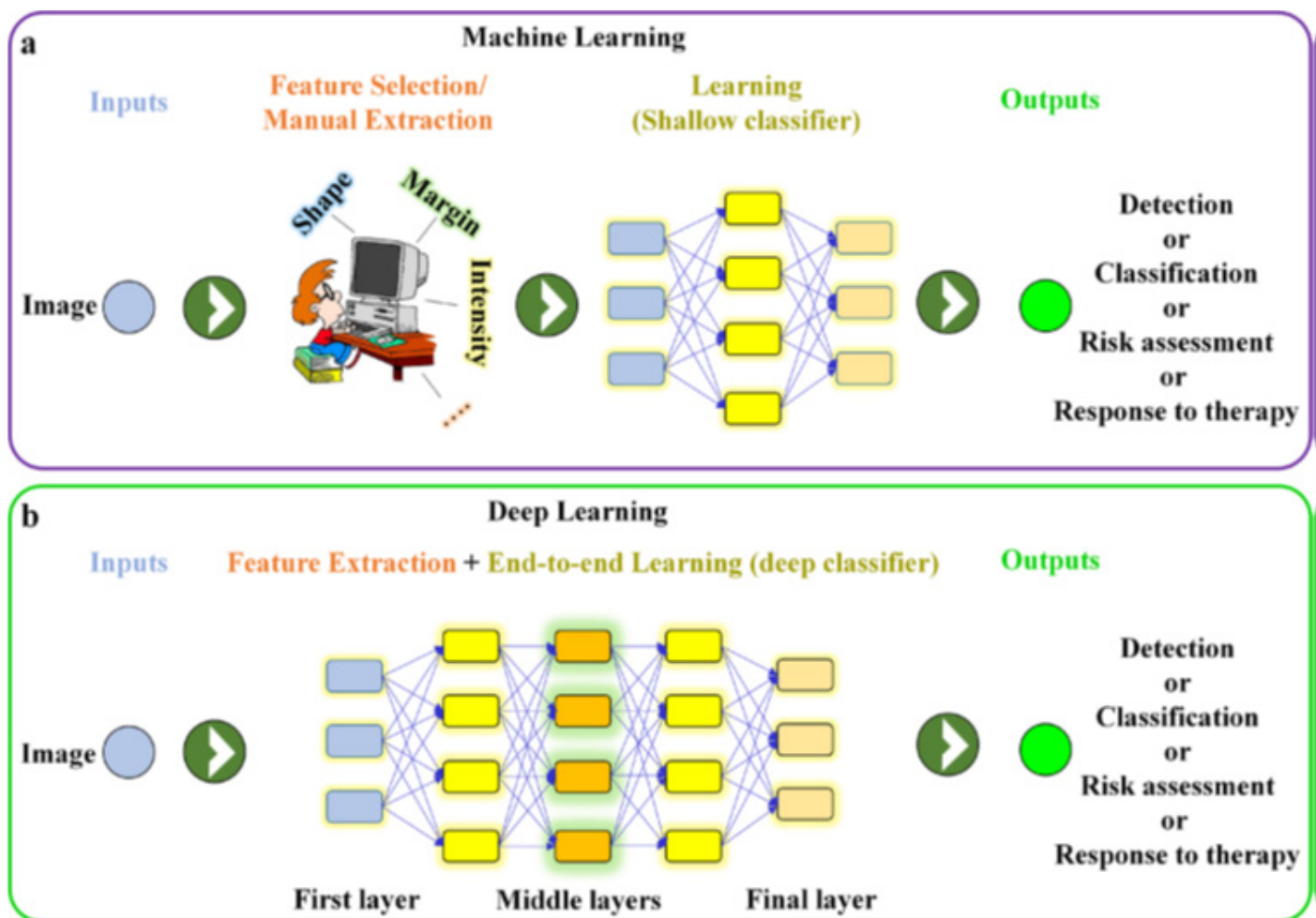


Figure 1: shows a schematic of an end-to-end deep learning network and a feature-based (human-engineered) machine learning network (e.g., using traditional CAD software). Computer-aided design, or CAD

learning lowers the amount of the required data sets for CNN training [24,26].

Digital Breast Tomosynthesis And Mammography Research On Cancer Categorization And Detection

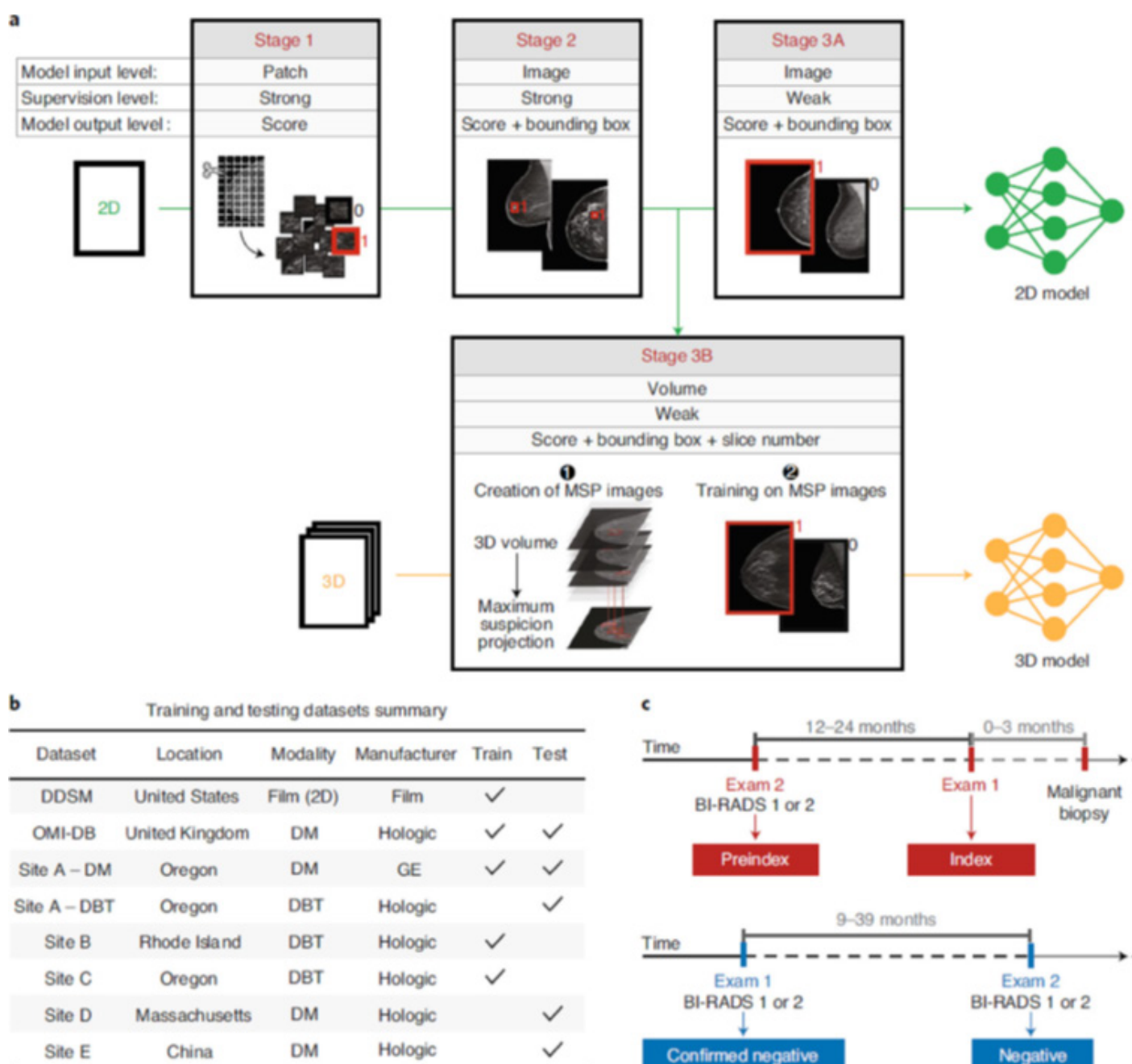
Breast cancer is diagnosed in more than 300,000 people annually in the United States alone. Mammography for screening reduces breast cancer mortality by 20–35%; however it is not a perfect technology [27]. Even among breast imaging specialists, there is substantial variation in the sensitivity and specificity of mammography, which range from 67 to 99 percent and [71 to 97] percent, respectively. 28 DL has the potential to boost these KPIs by lowering needless callbacks and raising cancer detection rates. Numerous reader and retrospective studies have previously demonstrated that AI models perform as well as or better than experienced radiologists [9,22,29–31]. Reader studies have combined general radiologists, fellowship-trained breast imagers, and occasionally even trainees, which is crucial to take into account when asserting the superiority of one method over another. It's important to highlight that whereas early

DL experiments relied on 2D mammography, more recent research has concentrated on DBT [7,29,32,33] which is a more difficult technical challenge but has the potential to enhance AI performance even more. DBT is more time-consuming for radiologists to interpret than 2D mammography by around 50%,³⁴ therefore AI solutions for DBT are being developed with clinical efficiency in mind rather than only to discover more tumours. Lotter et al. introduced a DL model for cancer detection that produced state-of-the-art performance for mammographic classification, demonstrating an area under the curve (AUC) of 0.945 in their retrospective analysis, in one of the most significant AI mammography/DBT investigations to date.²⁹ The DL model shown strong generalizability by outperforming five experienced breast imagers in a reader study, working for both 2D digital mammography and 3D DBT, and receiving external validation utilising imaging data from several national and one international location (**Figure 2**). Using a single standardised data set, independently assessed the performance of three commercial AI systems for mammography screening [35] Combining one of the three AI algorithms with

a human reader produced results that were superior to those of the human readers. Prospective clinical studies are required to open the door for clinical translation. The majority of these studies, which are presently accepting applicants, are testing how well the commercial AI software programmes Transpara (Screen Point Medical) and INSIGHT MMG (Lunit) perform in various clinical and geographical contexts. For instance, the ScreenTrust CAD trial (NCT04778670) will compare the Lunit software to single and double readings by radiologists, while the AITIC trial (NCT04949776) will assess whether Transpara can reduce the workload of a breast screening programme by 50% with non-inferior cancer detection and recall rate.

Figure 2 shows a multistage deep learning model's data summary and training. 29 (A) A stage-by-

stage illustration of model training Stage 1 provides a patch-level classification example. Stage 2 shows an intermediate phase where bounding boxes and likelihood ratings for malignancy were identified using complete mammography pictures and a detection-based model. In Stage 3A, the detection-based model is retrained using a multi-instance learning methodology, computing the maximum score across all bounding boxes in each entire mammography image to determine whether or not there is cancer present. A similar detection-based model for DBT was trained in Stage 3B utilising maximum suspicion projection images. (a) A summary of the training and testing data sets from multiple institutions. (c) An example of an exam definition that was used in the research [29]. Reprinted with Springer's permission [29]. Copyright for Nature Medicine 2021.



Mammography Process Improvement Using Ai

In the upcoming years, DL appears prepared to move beyond its current function as a tool for mammography decision-support and become an independent reader of “ultra-normal” mammograms. In the United States, screening mammograms are conducted on over 20 million 22 women year, and over 99 percent of them are perfectly normal. There might be considerable cost savings and effects on workflow if an independent AI reader approved even a small portion of these studies without consulting a radiologist. This has been the subject of several studies [41–43], with the findings indicating that AI could be able to exclude up to 20% of the mammograms with the lowest chance of cancer without missing malignancies. Larger studies are required to confirm these encouraging results. Prior to clinical use, regulatory, medical-legal, and ethical concerns of standalone AI should be further considered.

Calcification

The ACR BI-RADS vocabulary is typically used to categorise calcifications, a frequent mammography finding, as worrisome, probably benign, or benign [36]. To enhance the classification process and prevent pointless biopsies, DL tools are being developed because more than half of calcifications that are categorised as worrisome have benign pathology [37]. Although the quantity of the data sets is limited, several researchers have shown improvements in diagnostic accuracy using DL algorithms. However, more extensive validation studies are required [38–40].

Deep Learning For Determining Breast Cancer Risk

Aiming to improve breast cancer screening procedures, DL has been applied in one of the most significant AI-for-medical-imaging advances to date. Currently, to evaluate if a woman is at high risk of developing breast cancer, which necessitates further screening using contrast-enhanced MRI in addition to the standard-of-care yearly screening mammography, traditional risk assessment models like the Tyrer-Cuzick model are utilised. Yala et al. and others have created DL models that outperform the Tyrer-Cuzick model using mammograms^{10,44,45} (or MR images¹²) and that have been externally evaluated using sizable and varied data sets from the US, EU, and Asia (**Figure 3**) [10]. The use of one commercial AI technology

and one internal academic tool to predict future breast cancer risk based on mammography pictures will be evaluated in the prospective study Screen Trust MRI, NCT04832594, which will improve the triage of women to further screening with breast MRI. Manley et al⁴⁶ went a step further and showed that chemoprevention can reduce risk and their DL breast cancer risk score instrument is customizable. Additionally, DL tools have been created to automate the evaluation of mammographic breast density, and they have been used in radiology clinics, both academic and commercial [47,48].

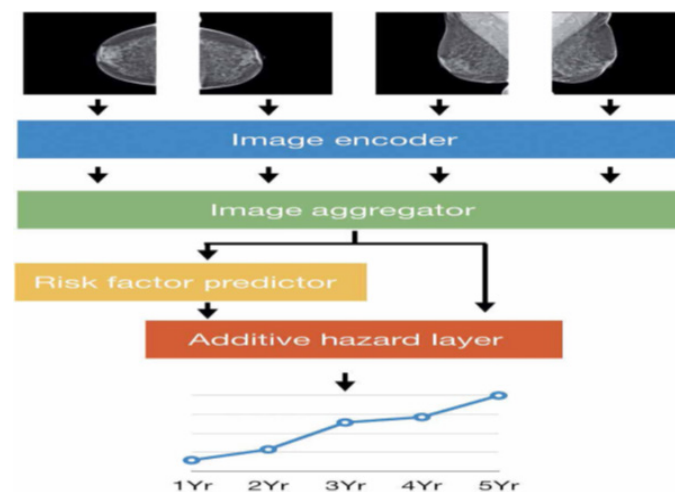


Figure 3 shows a schematic representation of the DL model for predicting breast cancer risk. 10 Four typical images of a single mammography are the model input. For all mammography views, the image encoder and image aggregator together generate a merged single vector. The DL model incorporates common clinical data (such as age and family history), and if any of these clinical variables are not accessible, a risk factor predictor module is utilised to fill in the gaps. The additive hazard layer, which incorporates imaging and clinical data, then forecasts breast cancer risk over a five-year period. Reprinted with permission from Science Translational Medicine, The American Association for the Advancement of Science, © 2021. DL, deep learning.

Ultrasound

Breast ultrasonography can be used as a diagnostic tool in the evaluation of mammographic or clinical findings as well as a supplemental screening modality (where it enhances the cancer detection rate over mammography alone, particularly in women with thick breasts) [49]. Unfortunately, ultrasonography frequently shows poor specificity and results in pointless biopsies. High inter reader variability is another

issue. 50 Breast ultrasound lesion segmentation, lesion detection, and lesion classification DL approaches have been developed for both automated and portable ultrasound in an effort to improve the diagnostic efficacy of ultrasound. Automated breast ultrasound generates thousands of images per patient exam, and so DL tools are particularly needed for lesion detection and to reduce interpretation time.⁵¹ DL-based segmentation methods are state of the art, outperforming conventional computerized methods [51–53]. DL has also been applied to lesion detection and classification. [54–62] with several reader studies reporting DL models that are equivalent or superior to radiologists [49,62,63], although in most of these studies, DL models were compared against general radiologists without subspecialty training in breast imaging, small data set sizes were used, and data were from a single institution.^{58,62} As such, more work is needed to demonstrate the generalizability of these models. As a prognostication tool, DL for breast ultrasonography has also been investigated. With AUCs up to 0.90, Zhou et al [58] and Zheng et al. [64] employed ultrasound pictures of primary breast cancers to make this prediction. Figure 4 shows how to use ultrasound pictures of primary breast cancer to predict axillary nodal metastases using DL.

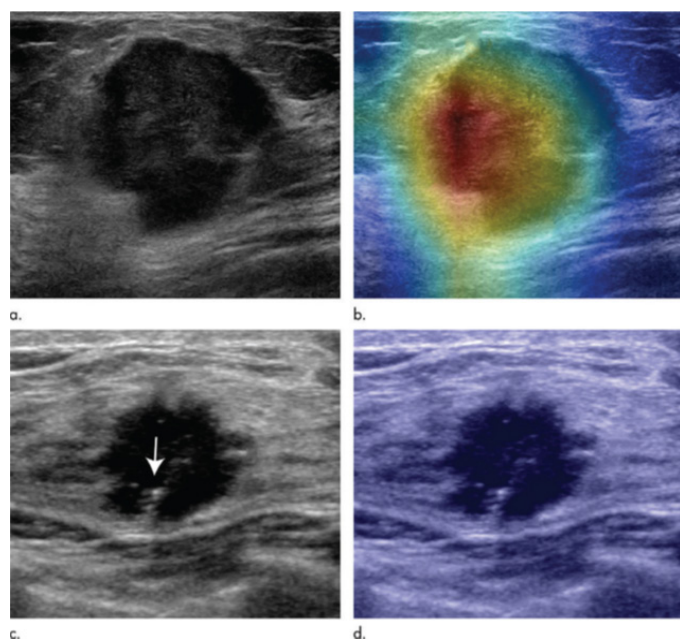


Figure 4 shows the ultrasound pictures of primary breast cancer in 2D and the DL-assisted prediction of clinically positive and negative lymph node metastases. ⁵⁸ In this case, the use of DL allowed for the precise prediction of positive lymph node metastasis in 67-year-old females (a, b) and negative lymph node metastasis in 46-year-old females (c, d). Radiology, ⁵⁸, reprinted with permission; 2020, Radiological Society of North America. Deep learning, or DL.

Imaging Of Magnetic Resonance

Breast MRI, the most sensitive technique for breast cancer diagnosis now on the market,⁶⁵ is indispensable for screening high-risk women, determining the severity of the illness, gauging treatment effectiveness, and solving diagnostic conundrums. However, the cost and length of the exams frequently restrict their utilisation. High-resolution dynamic contrast-enhanced MRI is an information-rich imaging technique with many imaging sequences (such as T1W, T2W, DWI, and dynamic pre- and post-contrast imaging) reflecting various features of the underlying pathophysiology (e.g. water content, vascular permeability, etc.). This data-richness offers DL significant potential to learn new patterns that reveal novel associations between imaging and illness, offering up new paths for personalised treatment in addition to automating straightforward breast MR interpretation tasks. DL has so far been used in the segmentation of breast MR images, lesion identification, risk assessment, and therapy response. ⁶⁶

Lesion Detection, Segmentation, And Classification

For 3D segmentation of breast MRI images, including segmentation of the whole breast, fibro glandular tissue (FGT), ^{69, 70} and mass lesions, ^{71, 72} DL is currently regarded as the most advanced technique (see Supplementary Material 1). Several organisations have used DL to identify and categorise lesions on breast MRIs⁷³⁻⁸¹ (see Supplementary Material 1 for details). A 4D breast MRI dataset's magnitude makes en masse model training computationally challenging. Therefore, image pre-processing pipelines that extract therapeutically important spatial and temporal information are the foundation of breast MRI DL models. The most common (and simplest) method enables the use of common 2D CNN architectures for model training by converting a 4D data set into a 2D maximum intensity projection (MIP) of the subtraction picture (post-contrast minus pre-contrast) [73]. Various strategies have been tried out by other parties, such as: (i) employing a "MIP" of CNN uses 3D lesion ROIs, not whole pictures, in its features [73,74]. (ii), thus lowering the necessary data size and permitting the adoption of a 3D CNN, [76] (iii) using multi parametric data (such as T2, DWI), [76-78] and (iv) combining classical machine learning approaches with DL feature extraction discovering classifiers. In actuality, all breast MRI DL publications are constrained by the tiny data set

size. the greatest studies to yet only including a few thousand breast cancer MRI scans Given the various sequences and the variances in protocol settings and naming standards, breast MRI tests are also notoriously difficult to curate.

Treatment Effectiveness And Risk Assessment

After intravenous contrast delivery, the background parenchymal enhancement (BPE) is a qualitative indicator of the augmentation of normal breast tissue. Similar to breast density, a radiologist's breast MRI report will contain information regarding BPE since it is a risk factor for breast cancer and to determine whether BPE limits the sensitivity for cancer detection [83]. When classifying BPE, radiologists exhibit high inter reader variability. BPE on breast MRI has been classified and segmented using DL, allowing for complete automation of this procedure.

Additionally, DL has been used to directly predict 5-year breast cancer risk from the breast MRI MIP picture, exceeding the gold standard Tyrer-Cuzick model in research similar to that done with mammography. Breast MRI data is particularly well-suited for more intricate DL-based prognostication because of its richness. Using pathology ground truth for the luminal A, luminal B, HER2+, and basal subtypes, DL using breast MRI images has been constructed to predict breast tumour molecular subtypes [86]. Using breast MRI data, other organisations have using DL to forecast the Oncotype Dx Recurrence Score. With good cross-validation accuracy, 89 DL has also been used to predict the axillary nodal status using breast MR images of the original tumour [90]. The use of DL methods to predict a patient's response to neo adjuvant chemotherapy is also a growing field of research. With AUCs of 0.81.93, the ground breaking I-SPY 2 study discovered that combinations of MRI characteristics can predict the pathologic treatment response. A number of teams are now combining pre- and post-neo adjuvant chemotherapy MRI scans with improved machine learning approaches to increase prediction ability. 13,14,91,94 Although a lot of this research is still in its early stages and only includes tiny data sets from a few universities, greater efforts in this field might eventually customise and improve cancer treatment.

Troubleshooting And Future Directions

Since 2016, the use of DL techniques in all facets of breast imaging has increased exponentially. Still,

additional effort is required in a number of crucial areas. First, in order to determine if AI technologies will perform as predicted in clinical settings, sizable multi-institutional prospective studies managed by impartial third parties are required. A number of AI decision-support technologies have already received FDA approval, and retrospective and small reader studies demonstrate that AI mammography tools perform on par with or better than professional radiologists. 95 However, thorough assessment of these tools in a prospective environment is essential prior to responsible clinical usage. AI mammography methods have been retrospectively verified in a few significant multi-institutional external validation studies, while ultrasound and particularly MRI still require similar validation effort. The development of AI models for breast MRI has been promising, however it is significant to highlight that practically all published research employed modest data sets and were conducted by a single institution without external validation.

Since breast MRI techniques vary so much between institutions and even within the same institution over time, DL breast MRI projects can be particularly difficult. However, a breast MRI scan contains a multitude of information, and it continues to be a fruitful field of research with the potential to uncover new and better approaches to tailor the care of breast cancer patients in order to optimise therapeutic benefit. More technological effort is required to optimise AI tools for DBT in the field of mammography. It follows that DBT should perform better than AI-enhanced 2D mammography since radiologists discover more tumours and receive fewer call backs when using DBT than when using 2D mammography. But as of yet, this is not the case. Modern AI development for DBT is a technically difficult endeavour. DBT exam sizes are significantly bigger than in 2D mammography, resulting in significantly higher computing expenses during training that may result in technological constraints. Moreover, compared to 2D digital mammography, DBT picture post-processing is considerably less uniform among manufacturers, with notable differences in both acquisition approach (i.e. hardware) and reconstruction technique (i.e. software). Smaller DBT data sets are frequently made available. Nevertheless, a number of recent research have found positive findings and aim to shorten interpretation times. It is crucial to address the related ethical, medicolegal, and regulatory challenges as more AI technologies are created that have the potential for clinical translation. This is crucial for

standalone AI programmes that interpret breast imaging examinations on their own (i.e., in cases when no human radiologist examines the pictures) [81]. There are a lot of unsolved concerns on the ethical front. It could be crucial in scenarios where AI functions as a “black box,” in which physicians act on the output of an AI tool without knowing how the algorithm came to its decision. When an AI technology misses a malignancy, who is responsible? How much should be under human control? An ethical issue with algorithms is prejudice. Constant care is required to manage possibly underrepresented minorities in the training data as AI models perform better on photos that match images in the training data set (e.g. racial groups, vendors, etc.). Additionally, more effort is required to increase the reliability of image normalisation methods so that DL models can more accurately generalise to data from institutions using various types of imaging gear or image post-processing software. Developing new legal mechanisms for thorough AI quality evaluation is also crucial. This might involve doing quality control tests on AI algorithms on a regular basis (much like imaging hardware does), as well as sometimes fine-tuning the algorithm to stop model performance from declining over time. Last but not least, one of the most startling findings in the literature to far is that using photos from many earlier time points does not result in better algorithm performance [30]. Although it is commonly established that having access to earlier mammograms significantly increases the diagnosis accuracy of breast imagers, the algorithms now in use cannot demonstrate equivalent gains. Clearly, there is room for technical advancement in this field.

CONCLUSION

In the upcoming years, the clinical environment of breast imaging is projected to undergo a significant change as DL technologies for breast imaging interpretation continue to advance quickly. Notably, DL mammography methods for detecting breast cancer and determining breast cancer risk exhibit performance at or above human levels, and prospective studies are required to open the door to clinical use. New opportunities for disease prognostication and individualised treatments are made possible by more work on DL for breast imaging. To minimise algorithmic biases, stop AI “performance drift,” and deal with the particular ethical, medico legal, and quality control challenges that DL algorithms offer, regulatory supervision is required when DL technologies are introduced into clinical practise.

REFERENCES

- [1] Shen D, Wu G, Suk HI. Deep learning in medical image analysis. *Annu Rev Biomed Eng* 2017; 19: 221–48. <https://doi.org/10.1146/annurev-bioeng-071516-044442>
- [2] Litjens G, Kooi T, Bejnordi BE, Setio AAA, Ciompi F, Ghafoorian M, et al. A survey on deep learning in medical image analysis. *Med Image Anal* 2017; 42: 60–88. <https://doi.org/10.1016/j.media.2017.07.005>
- [3] Chartrand G, Cheng PM, Vorontsov E, Drozdal M, Turcotte S, Pal CJ, et al. Deep learning: A primer for radiologists *Radiographics* 2017; 37: 2113–31. <https://doi.org/10.1148/rg.2017170077>
- [4] Esteva A, Kuprel B, Novoa RA, Ko J, Swetter SM, Blau HM, et al. Dermatologist-level classification of skin cancer with deep neural networks. *Nature* 2017; 542: 115–18. <https://doi.org/10.1038/nature21056>
- [5] Esteva A, Robicquet A, Ramsundar B, Kuleshov V, DePristo M, Chou K, et al. A guide to deep learning in healthcare. *Nat Med* 2019; 25: 24–29. <https://doi.org/10.1038/s41591-018-0316-z>
- [6] De Fauw J, Ledsam JR, Romera-Paredes B, Nikolov S, Tomasev N, Blackwell S, et al. Clinically applicable deep learning for diagnosis and referral in retinal disease. *Nat Med* 2018; 24: 1342–50. <https://doi.org/10.1038/s41591-018-0107-6>
- [7] Rodriguez-Ruiz A, Lång K, Gubern-Merida A, Broeders M, Gennaro G, Clauser P, et al. Stand-alone artificial intelligence for breast cancer detection in mammography: comparison with 101 radiologists. *J Natl Cancer Inst* 2019; 111: 916–22. <https://doi.org/10.1093/jnci/djy222>
- [8] Wu N, Phang J, Park J, Shen Y, Huang Z, Zorin M, et al. Deep neural networks improve radiologists’ performance in breast cancer screening. *IEEE Trans Med Imaging* 2020; 39: 1184–94. <https://doi.org/10.1109/TMI.2019.2945514>
- [9] McKinney SM, Sieniek M, Godbole V, Godwin J, Antropova N, Ashrafi H, et al. International evaluation of an AI system for breast cancer screening. *Nature* 2020; 577: 89–94. <https://doi.org/10.1038/s41586-019-1799-6>
- [10] Yala A, Mikhael PG, Strand F, Lin G, Smith K, Wan Y-L, et al. Toward robust mammography-based models for breast cancer risk. *Sci Transl Med* 2021; 13: 578. <https://doi.org/10.1126/scitranslmed.aba4373>

- [11] Dembrower K, Liu Y, Azizpour H, Eklund M, Smith K, Lindholm P, et al. Comparison of a deep learning risk score and standard mammographic density score for breast cancer risk prediction. *Radiology* 2020; 294: 265–72. <https://doi.org/10.1148/radiol.2019190872>
- [12] Portnoi T, Yala A, Schuster T, Barzilay R, Dontchos B, Lamb L, et al. Deep learning model to assess cancer risk on the basis of a breast MR image alone. *AJR Am J Roentgenol* 2019; 213: 227–33. <https://doi.org/10.2214/AJR.18.20813>
- [13] El Adoui M, Drisis S, Benjelloun M. Multi-input deep learning architecture for predicting breast tumor response to chemotherapy using quantitative MR images. *Int J Comput Assist Radiol Surg* 2020; 15: 1491–1500. <https://doi.org/10.1007/s11548-020-02209-9>
- [14] Ha R, Chin C, Karcich J, Liu MZ, Chang P, Mutasa S, et al. Prior to initiation of chemotherapy, can we predict breast tumor response? deep learning convolutional neural networks approach using a breast MRI tumor dataset. *J Digit Imaging* 2019; 32: 693–701. <https://doi.org/10.1007/s10278-018-0144-1>
- [15] Teuwen J, Moriakov N, Fedon C, Caballo M, Reiser I, Bakic P, et al. Deep learning reconstruction of digital breast tomosynthesis images for accurate breast density and patient-specific radiation dose estimation. *Med Image Anal* 2021; 71:102061. <https://doi.org/10.1016/j.media.2021.102061>
- [16] Kaye EA, Aherne EA, Duzgol C, Häggström I, Kobler E, Mazaheri Y, et al. Accelerating prostate diffusion-weighted MRI using a guided denoising convolutional neural network: retrospective feasibility study. *Radiol Artif Intell* 2020; 2: e200007. <https://doi.org/10.1148/ryai.2020200007>
- [17] Zeng G, Guo Y, Zhan J, Wang Z, Lai Z, Du X, et al. A review on deep learning MRI reconstruction without fully sampled k- space. *BMC Med Imaging* 2021; 21(1): 195. <https://doi.org/10.1186/s12880-021-00727-9>
- [18] Freer TW, Ullissey MJ. Screening mammography with computer-aided detection: prospective study of 12,860 patients in a community breast center. *Radiology* 2001; 220: 781–86. <https://doi.org/10.1148/radiol.2203001282>
- [19] Keen JD, Keen JM, Keen JE. Utilization of computer-aided detection for digital screening mammography in the united states, 2008 to 2016. *J Am Coll Radiol* 2018;15: 44–48. <https://doi.org/10.1016/j.jacr.2017.08.033>
- [20] Lehman CD, Wellman RD, Buist DSM, Kerlikowske K, Tosteson ANA, Miglioretti DL, et al. Diagnostic accuracy of digital screening mammography with and without computer-aided detection. *JAMA Intern Med* 2015; 175: 1828–37. <https://doi.org/10.1001/jamainternmed.2015.5231>
- [21] Krizhevsky A, Sutskever I, GEJainips H. Imagenet classification with deep convolutional neural networks. *Neural Information Processing Systems* 2012.
- [22] Geras KJ, Mann RM, Moy L. Artificial intelligence for mammography and digital breast tomosynthesis: current concepts and future perspectives. *Radiology* 2019; 293: 246–59. <https://doi.org/10.1148/radiol.2019182627>
- [23] Morgan MB, Mates JL. Applications of artificial intelligence in breast imaging. *Radiol Clin North Am* 2021; 59: 139–48. <https://doi.org/10.1016/j.rcl.2020.08.007>
- [24] LeCun Y, Bengio Y, Hinton G. Deep learning. *Nature* 2015; 521: 436–44. <https://doi.org/10.1038/nature14539>
- [25] Truhn D, Schradling S, Haarburger C, Schneider H, Merhof D, Kuhl C. Radiomic versus convolutional neural networks analysis for classification of contrast- enhancing lesions at multiparametric breast MRI. *Radiology* 2019; 290: 290–97. <https://doi.org/10.1148/radiol.2018181352>
- [26] Boström H, Knobbe A, Soares C, Papapetrou P. (n.d.). *Advances in Intelligent Data Analysis XV*. In: 15th International Symposium, IDA 2016. Cham: Springer International Publishing. <https://doi.org/10.1007/978-3-319-46349-0>
- [27] Elmore JG, Armstrong K, Lehman CD, Fletcher SW. Screening for breast cancer. *JAMA* 2005; 293: 1245–56. <https://doi.org/10.1001/jama.293.10.1245>
- [28] Lehman CD, Arao RF, Sprague BL, Lee JM, Buist DSM, Kerlikowske K, et al. National performance benchmarks for modern screening digital mammography: update from the breast cancer surveillance consortium. *Radiology* 2017; 283: 49–58. <https://doi.org/10.1148/radiol.2016161174>
- [29] Lotter W, Diab AR, Haslam B, Kim JG, Grisot G, Wu E, et al. Robust breast cancer detection in mammography and digital breast tomosynthesis using an annotation- efficient deep learning approach. *Nat Med* 2021; 27: 244–49. <https://doi.org/10.1038/s41591-021-1111-1>

org/10.1038/ s41591-020-01174-9

<https://doi.org/10.1016/j. patcog.2018.01.009>

- [30] Schaffter T, Buist DSM, Lee CI, Nikulin Y, Ribli D, Guan Y, et al. Evaluation of combined artificial intelligence and radiologist assessment to interpret screening mammograms. *JAMA Netw Open* 2020; 3: e200265. <https://doi.org/10.1001/jamanetworkopen.2020.0265>
- [31] Shen L, Margolies LR, Rothstein JH, Fluder E, McBride R, Sieh W. Deep learning to improve breast cancer detection on screening mammography. *Sci Rep* 2019; 9(1): 12495. <https://doi.org/10.1038/s41598-019-48995-4>
- [32] Conant EF, Toledano AY, Periaswamy S, Fotin SV, Go J, Boatsman JE, et al. Improving accuracy and efficiency with concurrent use of artificial intelligence for digital breast tomosynthesis. *Radiol Artif Intell* 2019; 1: e180096. <https://doi.org/10.1148/ryai.2019180096>
- [33] Pinto MC, Rodriguez-Ruiz A, Pedersen K, Hofvind S, Wicklein J, Kappler S, et al. Impact of artificial intelligence decision support using deep learning on breast cancer screening interpretation with single-view wide-angle digital breast tomosynthesis. *Radiology* 2021; 300: 529–36. <https://doi.org/10.1148/radiol.2021204432>
- [34] Dang PA, Freer PE, Humphrey KL, Halpern EF, Rafferty EA. Addition of tomosynthesis to conventional digital mammography: effect on image interpretation time of screening examinations. *Radiology* 2014; 270: 49–56. <https://doi.org/10.1148/radiol.13130765>
- [35] Salim M, Wählin E, Dembrower K, Azavedo E, Foukakis T, Liu Y, et al. External evaluation of 3 commercial artificial intelligence algorithms for independent assessment of screening mammograms. *JAMA Oncol* 2020; 6: 1581–88. <https://doi.org/10.1001/jamaoncol.2020.3321>
- [36] D'Orsi C. Breast imaging reporting and data system (BI-RADS). In: Lee CI, Lehman C, Bassett L, editors. *Breast Imaging*. New York: Oxford University Press; 2018.
- [37] Farshid G, Sullivan T, Downey P, Gill PG, Pieterse S. Independent predictors of breast malignancy in screen-detected microcalcifications: biopsy results in 2545 cases. *Br J Cancer* 2011; 105: 1669–75. <https://doi.org/10.1038/bjc.2011.466>
- [38] Wang J, Yang Y. A context-sensitive deep learning approach for microcalcification detection in mammograms. *Pattern Recognit* 2018; 78: 12–22.
- [39] Wang J, Yang X, Cai H, Tan W, Jin C, Li L. Discrimination of breast cancer with microcalcifications on mammography by deep learning. *Sci Rep* 2016; 6: 27327. <https://doi.org/10.1038/srep27327>
- [40] Liu H, Chen Y, Zhang Y, Wang L, Luo R, Wu H, et al. A deep learning model integrating mammography and clinical factors facilitates the malignancy prediction of BI-RADS 4 microcalcifications in breast cancer screening. *Eur Radiol* 2021; 31: 5902–12. <https://doi.org/10.1007/s00330-020-07659-y>
- [41] Rodriguez-Ruiz A, Lång K, Gubern- Merida A, Teuwen J, Broeders M, Gennaro G, et al. Can we reduce the workload of mammographic screening by automatic identification of normal exams with artificial intelligence? A feasibility study. *Eur Radiol* 2019; 29: 4825–32. <https://doi.org/10.1007/ s00330-019-06186-9>
- [42] Yala A, Schuster T, Miles R, Barzilay R, Lehman C. A deep learning model to triage screening mammograms: A simulation study. *Radiology* 2019; 293: 38–46. <https://doi.org/ 10.1148/radiol.2019182908>
- [43] Lång K, Dustler M, Dahlblom V, Åkesson A, Andersson I, Zackrisson S. Identifying normal mammograms in a large screening population using artificial intelligence. *Eur Radiol* 2021; 31: 1687–92. <https://doi.org/10. 1007/s00330-020-07165-1>
- [44] Yala A, Lehman C, Schuster T, Portnoi T, Barzilay R. A deep learning mammography- based model for improved breast cancer risk prediction. *Radiology* 2019; 292: 60–66. <https://doi.org/10.1148/radiol.2019182716>
- [45] Ha R, Chang P, Karcich J, Mutasa S, Pascual Van Sant E, Liu MZ, et al. Convolutional neural network based breast cancer risk stratification using a mammographic dataset. *Acad Radiol* 2019; 26: 544–49. <https://doi.org/10.1016/j.acra.2018.06.020>
- [46] Manley H, Mutasa S, Chang P, Desperito E, Crew K, Ha R. Dynamic changes of convolutional neural network- based mammographic breast cancer risk score among women undergoing chemoprevention treatment. *Clin Breast Cancer* 2021; 21: e312-18. <https://doi.org/10. 1016/j.clbc.2020.11.007>
- [47] Lehman CD, Yala A, Schuster T, Dontchos B, Bahl M, Swanson K, et al. Mammographic breast density assessment using deep learning: clinical implementation. *Radiology* 2019; 290: 52–58.

- <https://doi.org/10.1148/radiol.2018180694>
- [48] Chang K, Beers AL, Brink L, Patel JB, Singh P, Arun NT, et al. Multi-institutional assessment and crowdsourcing evaluation of deep learning for automated classification of breast density. *J Am Coll Radiol* 2020; 17: 1653–62. <https://doi.org/10.1016/j.jacr.2020.05.015>
- [49] Kim J, Kim HJ, Kim C, Kim WH. Artificial intelligence in breast ultrasonography. *Ultrasonography* 2021; 40: 183–90. <https://doi.org/10.14366/usg.20117>
- [50] Mango VL, Sun M, Wynn RT, Ha R. Should we ignore, follow, or biopsy? impact of artificial intelligence decision support on breast ultrasound lesion assessment. *AJR Am J Roentgenol* 2020; 214: 1445–52. <https://doi.org/10.2214/AJR.19.21872>
- [51] Yap MH, Pons G, Marti J, Ganau S, Sentis M, Zwigelaar R, et al. Automated breast ultrasound lesions detection using convolutional neural networks. *IEEE J Biomed Health Inform* 2018; 22: 1218–26. <https://doi.org/10.1109/JBHI.2017.2731873>
- [52] Yap MH, Edirisinghe EA, Bez HE. A novel algorithm for initial lesion detection in ultrasound breast images. *J Appl Clin Med Phys* 2008; 9: 181–99. <https://doi.org/10.1120/jacmp.v9i4.2741>
- [53] Virmani J, Kumar V, Kalra N, Khandelwal N. Neural network ensemble based CAD system for focal liver lesions from B-mode ultrasound. *J Digit Imaging* 2014; 27: 520–37. <https://doi.org/10.1007/s10278-014-9685-0>
- [54] Lei Y, He X, Yao J, Wang T, Wang L, Li W, et al. Breast tumor segmentation in 3D automatic breast ultrasound using mask scoring R-CNN. *Med Phys* 2021; 48: 204–14. <https://doi.org/10.1002/mp.14569>
- [55] Zhou Y, Chen H, Li Y, Liu Q, Xu X, Wang S, et al. Multi-task learning for segmentation and classification of tumors in 3D automated breast ultrasound images. *Med Image Anal* 2021; 70: 101918. <https://doi.org/10.1016/j.media.2020.101918>
- [56] Byra M, Galperin M, Ojeda-Fournier H, Olson L, O’Boyle M, Comstock C, et al. Breast mass classification in sonography with transfer learning using a deep convolutional neural network and color conversion. *Med Phys* 2019; 46: 746–55. <https://doi.org/10.1002/mp.13361>
- [57] Han S, Kang H-K, Jeong J-Y, Park M-H, Kim W, Bang W-C, et al. A deep learning framework for supporting the classification of breast lesions in ultrasound images. *Phys Med Biol* 2017; 62: 7714–28. <https://doi.org/10.1088/1361-6560/aa82ec>
- [58] Zhou L-Q, Wu X-L, Huang S-Y, Wu G-G, Ye H-R, Wei Q, et al. Lymph node metastasis prediction from primary breast cancer US images using deep learning. *Radiology* 2020; 294: 19–28. <https://doi.org/10.1148/radiol.2019190372>
- [59] Costa MGF, Campos JPM, de Aquino E, Aquino G, de Albuquerque Pereira WC, Costa Filho CFE. Evaluating the performance of convolutional neural networks with direct acyclic graph architectures in automatic segmentation of breast lesion in US images. *BMC Med Imaging* 2019; 19(1): 85. <https://doi.org/10.1186/s12880-019-0389-2>
- [60] Hu Y, Guo Y, Wang Y, Yu J, Li J, Zhou S, et al. Automatic tumor segmentation in breast ultrasound images using a dilated fully convolutional network combined with an active contour model. *Med Phys* 2019; 46: 215–28. <https://doi.org/10.1002/mp.13268>
- [61] Zhuang Z, Li N, Joseph Raj AN, Mahesh VGV, Qiu S. An RDAU-NET model for lesion segmentation in breast ultrasound images. *PLoS One* 2019; 14(8): e0221535. <https://doi.org/10.1371/journal.pone.0221535>
- [62] Qian X, Pei J, Zheng H, Xie X, Yan L, Zhang H, et al. Prospective assessment of breast cancer risk from multimodal multiview ultrasound images via clinically applicable deep learning. *Nat Biomed Eng* 2021; 5: 522–32. <https://doi.org/10.1038/s41551-021-00711-2>
- [63] Kim S-Y, Choi Y, Kim E-K, Han B-K, Yoon JH, Choi JS, et al. Deep learning-based computer-aided diagnosis in screening breast ultrasound to reduce false-positive diagnoses. *Sci Rep* 2021; 11(1): 395. <https://doi.org/10.1038/s41598-020-79880-0>
- [64] Zheng X, Yao Z, Huang Y, Yu Y, Wang Y, Liu Y, et al. Deep learning radiomics can predict axillary lymph node status in early-stage breast cancer. *Nat Commun* 2020; 11(1): 1236. <https://doi.org/10.1038/s41467-020-15027-z>
- [65] Mann RM, Cho N, Moy L. Breast MRI: state of the art. *Radiology* 2019; 292: 520–36. <https://doi.org/10.1148/radiol.2019182947>
- [66] Sheth D, Giger ML. Artificial intelligence in the interpretation of breast cancer on MRI. *J Magn Reson Imaging* 2020; 51: 1310–24. <https://doi.org/10.1002/jmri.26878>
- [67] Zhang L, Mohamed AA, Chai R, Guo Y, Zheng B,

- Wu S. Automated deep learning method for whole-breast segmentation in diffusion-weighted breast MRI. *J Magn Reson Imaging* 2020; 51: 635–43. <https://doi.org/10.1002/jmri.26860>
- [68] Piantadosi G, Sansone M, Fusco R, Sansone C. Multi-planar 3D breast segmentation in MRI via deep convolutional neural networks. *Artif Intell Med* 2020; 103: 101781. <https://doi.org/10.1016/j.artmed.2019.101781>
- [69] Dalmış MU, Litjens G, Holland K, Setio A, Mann R, Karssemeijer N, et al. Using deep learning to segment breast and fibroglandular tissue in MRI volumes. *Med Phys* 2017; 44: 533–46. <https://doi.org/10.1002/mp.12079>
- [70] Zhang Y, Chen J-H, Chang K-T, Park VY, Kim MJ, Chan S, et al. Automatic breast and fibroglandular tissue segmentation in breast MRI using deep learning by a fully-convolutional residual neural network U-net. *Acad Radiol* 2019; 26: 1526–35. <https://doi.org/10.1016/j.acra.2019.01.012>
- [71] Zhang Y, Chan S, Park VY, Chang K-T, Mehta S, Kim MJ, et al. Automatic detection and segmentation of breast cancer on MRI using mask R-CNN trained on non-fat-sat images and tested on fat-sat images. *Acad Radiol* 2022; 29 Suppl 1: S135-44. <https://doi.org/10.1016/j.acra.2020.12.001>
- [72] van der Velden BHM, Janse MHA, Ragusi MAA, Loo CE, Gilhuijs KGA. Volumetric breast density estimation on MRI using explainable deep learning regression. *Sci Rep* 2020; 10(1): 18095. <https://doi.org/10.1038/s41598-020-75167-6>
- [73] Antropova N, Abe H, Giger ML. Use of clinical MRI maximum intensity projections for improved breast lesion classification with deep convolutional neural networks. *J Med Imaging (Bellingham)* 2018; 5: 014503. <https://doi.org/10.1117/1.JMI.5.1.014503>
- [74] Hu Q, Whitney HM, Li H, Ji Y, Liu P, Giger ML. Improved classification of benign and malignant breast lesions using deep feature maximum intensity projection MRI in breast cancer diagnosis using dynamic contrast-enhanced MRI. *Radiol Artif Intell* 2021;3: e200159. <https://doi.org/10.1148/ryai.2021200159>
- [75] Fujioka T, Yashima Y, Oyama J, Mori M, Kubota K, Katsuta L, et al. Deep-learning approach with convolutional neural network for classification of maximum intensity projections of dynamic contrast-enhanced breast magnetic resonance imaging. *Magn Reson Imaging* 2021; 75: 1–8. <https://doi.org/10.1016/j.mri.2020.10.003>
- [76] Dalmış MU, Gubern-Mérida A, Vreemann S, Bult P, Karssemeijer N, Mann R, et al. Artificial intelligence-based classification of breast lesions imaged with a multiparametric breast MRI protocol with ultrafast DCE- MRI, T2, and DWI. *Invest Radiol* 2019; 54: 325–32. <https://doi.org/10.1097/RLI.0000000000000544>
- [77] Parekh VS, Macura KJ, Harvey SC, Kamel IR, Eikhoul R, Bluemke DA, et al. Multiparametric deep learning tissue signatures for a radiological biomarker of breast cancer: preliminary results. *Med Phys* 2020; 47: 75–88. <https://doi.org/10.1002/mp.13849>
- [78] Hu Q, Whitney HM, Giger ML. A deep learning methodology for improved breast cancer diagnosis using multiparametric MRI. *Sci Rep* 2020; 10(1): 10536. <https://doi.org/10.1038/s41598-020-67441-4>
- [79] Zhou J, Luo L-Y, Dou Q, Chen H, Chen C, Li G-J, et al. Weakly supervised 3D deep learning for breast cancer classification and localization of the lesions in MR images. *J Magn Reson Imaging* 2019; 50: 1144–51. <https://doi.org/10.1002/jmri.26721>
- [80] Liu MZ, Swintelski C, Sun S, Siddique M, Desperito E, Jambawalikar S, et al. Weakly supervised deep learning approach to breast MRI assessment. *Acad Radiol* 2022; 29 Suppl 1: S166-72. <https://doi.org/10.1016/j.acra.2021.03.032>
- [81] Hickman SE, Baxter GC, Gilbert FJ. Adoption of artificial intelligence in breast imaging: evaluation, ethical constraints and limitations. *Br J Cancer* 2021; 125: 15–22. <https://doi.org/10.1038/s41416-021-01333-w>
- [82] Adachi M, Fujioka T, Mori M, Kubota K, Kikuchi Y, Xiaotong W, et al. Detection and diagnosis of breast cancer using artificial intelligence based assessment of maximum intensity projection dynamic contrast-enhanced magnetic resonance images. *Diagnostics (Basel)* 2020; 10(5): E330. <https://doi.org/10.3390/diagnostics10050330>
- [83] Watt GP, Sung J, Morris EA, Buys SS, Bradbury AR, Brooks JD, et al. Association of breast cancer with MRI background parenchymal enhancement: the IMAGINE case-control study. *Breast Cancer Res* 2020; 22: 138. <https://doi.org/10.1186/s13058-020-01375-7>
- [84] Ha R, Chang P, Mema E, Mutasa S, Karcich J, Wynn RT, et al. Fully automated convolutional neural network method for quantification of breast MRI fibroglandular tissue and background parenchymal

- p>enhancement. J Digit Imaging 2019; 32: 141–47.
- <https://doi.org/10.1007/s10278-018-0114-7>
- [85] Eskreis-Winkler S, Sutton EJ, D'Alessio D, Gallagher K, Saphier N, Stember J, et al. (n.d.). Breast MRI background parenchymal enhancement (BPE) categorization using deep learning: outperforming the radiologist. J Magn Reson Imaging.. doi: <https://doi.org/10.1002/jmri.27429>
- [86] Zhang Y, Chen J-H, Lin Y, Chan S, Zhou J, Chow D, et al. Prediction of breast cancer molecular subtypes on DCE-MRI using convolutional neural network with transfer learning between two centers. Eur Radiol 2021; 31: 2559–67. <https://doi.org/10.1007/s00330-020-07274-x>
- [87] Liu W, Cheng Y, Liu Z, Liu C, Cattell R, Xie X, et al. Preoperative prediction of ki-67 status in breast cancer with multiparametric MRI using transfer learning. Acad Radiol 2021; 28: e44-53. <https://doi.org/10.1016/j.acra.2020.02.006>
- [88] Ha R, Mutasa S, Karcich J, Gupta N, Pascual Van Sant E, Nemer J, et al. Predicting breast cancer molecular subtype with MRI dataset utilizing convolutional neural network algorithm. J Digit Imaging 2019; 32: 276–82. <https://doi.org/10.1007/s10278-019-00179-2>
- [89] Ha R, Chang P, Mutasa S, Karcich J, Goodman S, Blum E, et al. Convolutional neural network using a breast MRI tumor dataset can predict oncotype dx recurrence score. J Magn Reson Imaging 2019; 49: 518–24. <https://doi.org/10.1002/jmri.26244>
- [90] Ha R, Chang P, Karcich J, Mutasa S, Fardanesh R, Wynn RT, et al. Axillary lymph node evaluation utilizing convolutional neural networks using MRI dataset. J Digit Imaging 2018; 31: 851–56. <https://doi.org/10.1007/s10278-018-0086-7>
- [91] Ha R, Chang P, Karcich J, Mutasa S, Van Sant EP, Connolly E, et al. Predicting post neoadjuvant axillary response using a novel convolutional neural network algorithm. Ann Surg Oncol 2018; 25: 3037–43. <https://doi.org/10.1245/s10434-018-6613-4>
- [92] Cooper K, Meng Y, Harnan S, Ward S, Fitzgerald P, Papaioannou D, et al. Positron emission tomography (PET) and magnetic resonance imaging (MRI) for the assessment of axillary lymph node metastases in early breast cancer: systematic review and economic evaluation. Health Technol Assess 2011; 15: 1–134. <https://doi.org/10.3310/hta15040>
- [93] Li W, Newitt DC, Gibbs J, Wilmes LJ, Jones EF, Arasu VA, et al. Predicting breast cancer response to neoadjuvant treatment using multi-feature MRI: results from the I-SPY 2 TRIAL. NPJ Breast Cancer 2020; 6: 63. <https://doi.org/10.1038/s41523-020-00203-7>
- [94] Choi JH, Kim H-A, Kim W, Lim I, Lee I, Byun BH, et al. Early prediction of neoadjuvant chemotherapy response for advanced breast cancer using PET/MRI image deep learning. Sci Rep 2020; 10(1): 21149. <https://doi.org/10.1038/s41598-020-77875-5>
- [95] Tadavarthi Y, Vey B, Krupinski E, Prater A, Gichoya J, Safdar N, et al. The state of radiology AI: considerations for purchase decisions and current market offerings. Radiol Artif Intell 2020; 2: e200004. <https://doi.org/10.1148/ryai.2020200004>
- [96] Eskreis-Winkler S, Onishi N, Pinker K, Reiner J, Kaplan J, Morris EA, et al. Using deep learning to improve nonsystemic viewing of breast cancer on MRI. Journal of Breast Imaging 2021; 3: 201–7.